



Karl Storz Lecture

# Thoracoscopic approach for oesophageal atresia: A real game changer?☆

Dariusz Patkowski

Pediatric Surgery and Urology Department, Wrocław Medical University, Borowska 213, Wrocław 50-556, Poland



## ARTICLE INFO

### Article history:

Received 28 September 2022

Accepted 11 October 2022

### Keywords:

Oesophageal atresia

Thoracoscopy

Long gap oesophageal atresia

## ABSTRACT

Almost 23 years have passed since the first thoracoscopic procedure was done. However, according to the recent study in USA, only 16% of newborns with oesophageal atresia and distal tracheoesophageal fistula are managed by thoracoscopic approach with a very high 53% conversion rate. The aim of presentation based on experience of one paediatric surgery centre is to prove that thoracoscopic approach for this malformation is a powerful tool with a potential to change the current results. It requires considerable experience that comes only from the high number of operated cases. The technique is one amongst the many others means which taken together may really help to improve the results. Thus, the question of centralisation for special rare congenital malformations comes back to mind. Is it rational to operate on only 2 or 3 cases a year in a single centre, or is it the time for centralisation and close co-operation, as has been done with biliary atresia treatment in the UK?

*Level of evidence:* III.

© 2022 The Author(s). Published by Elsevier Inc.

This is an open access article under the CC BY-NC-ND license

(<http://creativecommons.org/licenses/by-nc-nd/4.0/>)

## 1. Introduction

It is a special day for me to stand in front of you. My first international presentation took place in 1991 at the BAPS Congress held in Budapest, Hungary. It was beyond my imagination that in the journey of my career, I will now arrive at the station named BAPS Congress 2022. It is a great honour and I regard it as one of supreme distinction for paediatric surgeon presenting to you the Storz Lecture.

The final successful treatment of patients born with oesophageal atresia involves many factors and the surgical technique is only one of the many means. Almost 23 years have passed since the first thoracoscopic procedure was done by Thom Lobe and Steven Rothenberg [1]. However, considering its application in clinical practise the reality is still not so bright. According to the recent study in USA only 16% of newborns with oesophageal atresia (OA) and distal tracheoesophageal fistula (TOF) are managed by thoracoscopic approach with a very high 53% conversion rate [2]. It is even worse if we consider thoracoscopic approach for type A and B OA often regarded as long gap OA (LGOA).

Today I am going to talk about thoracoscopic approach for oesophageal atresia as a real game changer, a technique already known for two decades. So where is the problem? I will discuss it later. The title of my lecture is provocative and suggests the new opportunities for infants with oesophageal atresia. My objective today is to present you with my experience and to convince all of you at the audience that the thoracoscopic technique in the right hands has a potential to be a real game changer and should be treated as a procedure of choice.

### 1.1. Personal story

Let me begin by telling you my personal story. I had the opportunity to be the witness of great changes in paediatric surgery thanks to the progress in scientific knowledge, medical equipment, and technology. Oesophageal atresia was always of special importance to me and probably for many others paediatric surgeons. I remember one of my mentors and teachers Professor Czernik's saying that results of oesophageal atresia treatment are a kind of a litmus paper and directly reflect the level of paediatric surgery in the country. Unfortunately, at the beginning of my surgical carrier there was much work to be done to improve the results of OA/TOF treatment in Poland.

There were important moments that shaped me as paediatric surgeon. I graduated from Wrocław Medical University in 1986 since then I have been employed in Paediatric Surgery and Urology Department of the same University. Poland was a communist

Abbreviations: OA, oesophageal atresia; TOF, distal tracheoesophageal fistula; LGOA, long gap oesophageal atresia.

☆ Based on the Storz Lecture, British Association of Paediatric Surgeons, Birmingham July 2022

E-mail address: [dariusz.patkowski@umw.edu.pl](mailto:dariusz.patkowski@umw.edu.pl)

country at that time with problematic surroundings. My paediatric surgeon's foundations were built on a textbook "Neonatal Surgery" by Peter Paul Rickham published in 1969 and translated into Polish in 1975. Great Britain was regarded in Poland as a synonym for the centre of excellence for paediatric surgery but was well out of my reach to actually be visited. It may be difficult to understand from the viewpoint of today's global travelling and ease of communication but travel to the Western world at that time was much restricted both for political and economic reasons. Indeed, the first time I visited the West was when I was 28 years old. By chance, it was Bremen in West Germany where I got a scholarship from a German paediatric surgery. Bremen was famous for Prof. Fritz Rehbein and one of the leading places for the treatment of oesophageal atresia – the cause of my interest at that time. Later, I visited many other famous paediatric centres around the World amongst them Luzern in Switzerland, Bremen, Glasgow, New York, and Kobe in Japan, always trying to bring back to Poland the best possible knowledge and experience.

My experience with minimally invasive surgery started in 1995 when we received our first equipment for laparoscopic and endoscopic surgery. Professor Czernik's opinion at that time was: "we do not really need it, as a paediatric surgeon operates through a small incision". We can still hear this in many places today of course, but he knew that a new era was coming, and he encouraged me to educate and develop in this direction.

Ten years later in 2005, there was IPEG Meeting in Venice that changed my surgery forever. My friend and great Polish paediatric surgeon, Professor Piotr Czauderna taught me how to do a sliding knot! Combining my experience in endoscopic surgery with such a small trick for perfect endoscopic suturing allowed me to do many advanced endoscopic procedures amongst them thoracoscopic OA repair. Next day there was a session about thoracoscopic surgery for OA/TOF. My chief Prof. Czernik looked at me and asked: "Darek can we do it?" After two months of exercise and mastering the sliding knot technique on 18th August 2005 we operated on the first case in Poland that was successful. Today, my personal experience is 235 primary cases operated in Wroclaw and many other hospitals in Poland and all around the world.

In 2009, I applied as participant for the 1st International Hands-on Course in fetal and Neonatal Endoscopic Surgery organized by Jorge Correia Pinto in Braga, Portugal with a faculty of the most famous endoscopic paediatric surgeons. It was another turning point in my career. I was invited to be a member of the faculty for the next courses. I realized that our achievements in Wroclaw were interesting to others.

### 1.2. Thoracoscopic repair of oesophageal atresia

Since the first case, all consecutive cases managed in Wroclaw were operated only by thoracoscopic approach as a procedure of choice. There were 172 primary patients with all types of oesophageal atresia with around 12–18 cases a year in recent times. Two specialists are involved in their treatment and at least one of them is always present in the operating room. Residents are doing a part of the procedure depending on their experience including dissection and suturing. Our results for type C and D OA are presented in Table 1.

Let me present shortly the main aspects of the technique that has evolved with time and growing experience (Table 2). From my experience each case of OA/TOF considered for surgical approach is also suitable for thoracoscopic approach. Moreover, it is possible to successfully repair cases weighing 1000 g, but it is really challenging. In such a case it is reasonable only to close the distal fistula and to perform the final anastomosis later after gaining more weight. The same treatment is recommended for patients in poor general condition and severe respiratory insufficiency.

**Table 1**  
Results of Wroclaw's OA thoracoscopic repair Type C and D - 2005–2022.

Number of cases 145	
<b>Operative Details</b>	
Operation Time	1:31 h (range 46 min - 4:05 hr)
Conversion	0 (of 145 cases, 0%)
<b>Complications</b>	
Leakage	N = 10 cases (6.9%)
Anastomosis dilatation (>1)	N = 34 (of 134 cases, 25.4%)
Recurrent TEF	N = 1 (of 133 cases, 0.7%)
Fundoplication	N = 5 (of 134 cases, 3.7%)
<b>Outcome</b>	
Early mortality (<30days)	N = 7 cases (4.8%)
Late mortality (> 30days)	N = 5 cases (3.4%)

**Table 2**  
Crucial points for successful thoracoscopic OA/TOF repair.

- Preoperative bronchoscopy
- Prone position at the operative table border
- bilateral lung ventilation
- anatomical tissue dissection
- No electrosurgery, no suction, no irrigation
- Perfect technique of sliding knot for oesophageal anastomosis
- Short time of operative procedure

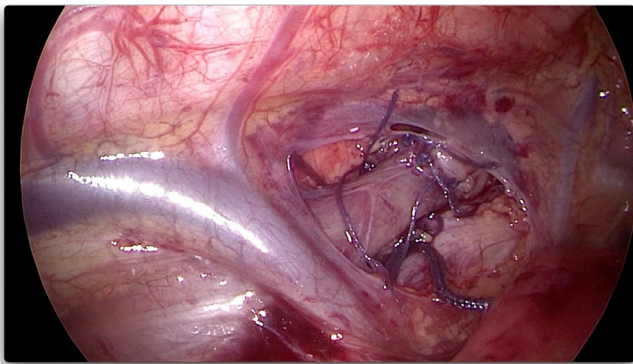
Nowadays, the procedure always starts with a rigid bronchoscopy. It gives much information about the larynx, the trachea, and the fistula location. After the patient is intubated, the central line is placed. Bilateral lung ventilation is always used. We have found that the best position is the prone one at the side of the operating table. It gives the best access to the posterior mediastinum as the lung goes down with the gravity. We use one 5 mm trocar and two 3 mm trocars placed around the outer border of the scapula with 5 mm oblique scope, 3 mm instruments and 4–6 mmHg of working pressure. There is no need for an extra trocar or a lung retractor. Usually within 5–10 min the lung collapses substantially to show the posterior mediastinum. The azygos vein serves as anatomical landmark and is always left intact. Leaving a vein intact may improve blood supply to surrounding tissues. Depending on the preoperative bronchoscopy the distal fistula lies in mediastinum under the vein if it enters the trachea at the bifurcation or above in cephalic direction if enters the posterior wall. The fistula is transfixed with the suture or simply ligated with a sliding knot as we do in all recent cases. Previously we used to close it with 5 mm clips. In some cases, we noted that clips disappeared on control X-ray and there was even one case that expectorated the clip 3 years after the procedure!

One of the crucial points of this technique is a complete elimination of a surgical diathermy for tissue dissection. In the majority of cases and in all recent ones, it is a blunt dissection. Sometimes the strong fibrous band between the upper pouch and posterior trachea requires division with scissors. The main dissection includes the upper pouch mobilization with minimal dissection of the lower one. In our experience it is completely blood-less procedure. Therefore, no irrigation and suction is needed (Fig. 1). Regardless of the type of OA and number of stages performed for each case, our patients have not required blood transfusion. I think this is a real advantage and can be attributed to the thoracoscopic technique itself.

The anastomosis is always done using sliding knots. Before the anastomosis begins the tip of the upper pouch is cut off partially and used for pouch traction. Similarly, the distal pouch is partially cut off from the fistula to prevent its contraction and disappearing in mediastinum. Both are cut off completely later after placing one or two sutures. At that moment the nasogastric tube is advanced down to the stomach. It does not matter whether the anastomosis

**Table 3**  
Results for consecutive long gap OA treatment at Wroclaw (author's personal involvement) 2008 – 2022.

Stages	No of cases	Remarks
1 stage	1	Birth weight 750 g, kept on total parenteral nutrition without gastrostomy (PICU Krakow), primary anastomosis at 56th day
2 stages	14	Thoracoscopic Foker's technique (N = 1) Internal traction (N = 13) Without gastrostomy (N = 8) Death - cardiac anomaly (N = 1)
3 stages	6	No gastrostomy
4 stages	1	No gastrostomy
5 stages	1	Leakage after 2nd stage, repaired thoracoscopically
6 stages	1	Leakage after 2nd stage, repaired thoracoscopically
Not completed (death)	2	Death because of associated malformations
Final Collis-Nissen open repair	1	Upper pouch perforation after second thoracoscopy, emergency oesophagostomy
<b>Total of cases</b>	<b>27</b>	Type A (N = 11) Type B (N = 16) All cases except 2 had internal traction



**Fig. 1.** Operative field view at the end of procedure- no electrosurgery, no suction, no irrigation.

over the nasogastric tube starts from the posterior, lateral or anterior wall of the oesophagus. One can easily rotate the oesophagus around using the already placed sutures. The oesophageal anastomosis is completed usually with 6–8 single absorbable braided sutures. In my experience, the anastomosis is almost always possible for primary repair in type C and D. This was done in two stages for 5 (3.3%) of 145 cases because of patient instability or because in operator's opinion the anastomosis was too difficult. A nasogastric tube is left in place until the fifth postoperative day when the anastomotic integrity is checked with a contrast study. Enteral feeding through the nasogastric tube starts on the 2nd postoperative day and is replaced with oral feeding after contrast study. We have had 10 (of 145 cases, 6.9%) leakages of type C and D OA with only 2 (2.2%) for the last 92 cases. All leakages were treated conservatively with chest drainage. Most procedures for type C OA are completed within one hour, seldom lasting longer. Thus far, we have not had a conversion for types C or D. Only 4 (of 145 cases, 2.8%) have required gastrostomy and there has been no gastrostomy for the last 67 consecutive cases. To date, we have screened 79 cases repaired with our thoracoscopic approach for chest deformation and have found no rib fusion or scoliosis of more than 20%.

### 1.3. Thoracoscopy for long gap oesophageal repair

We have started with a thoracoscopic staged LGOA repair using internal traction sutures. The idea of internal traction sutures was based on Foker's technique. There are different definitions of LGOA however, and in my opinion, it should be reserved only for type A and B to avoid any confusions and data misinterpretation. At the beginning of our experience the time between stages was 4

weeks, but later after having talks with David van der Zee (surgeon in Utrecht, Netherlands) was shortened to 1–5 days apart to avoid the gastrostomy placement. It became clear that almost all long gap cases managed with internal traction succeeded with thoracoscopic oesophageal anastomosis (Table 3).

The same principles of thoracoscopic approach as described earlier are used at the beginning of the procedure for LGOA patients. Having both pouches fully mobilized, the internal traction suture between them is placed. It passes through the tips of both oesophageal ends, taking a good bite of tissue. To prevent any leakage and tissue disruption two clips are placed across the tips of both oesophageal pouches taking the threads into the clips. In this way, the traction force is dispersed along the clips instead of tissue puncture spot and one can use the greater traction force. For clips placement one trocar is exchanged into 5 mm to accommodate a clip applicator. Two sliding knots are created and both oesophageal ends are approached step by step. It is in the surgeon's judgement how much traction force to use. Usually there is no need for a chest drain at this stage. The next stage procedure is scheduled 2–5 days later or even the next day as it was with the last operated case. The trocars are placed using the previous skin incisions. Usually only very soft adhesions are found at the mediastinum around the pouches and the traction suture. They are dissected easily. If both pouches overcome each other without significant tension, the anastomosis is started. In other case the previously created sliding knots are unlocked and are used again to get pouches closer. It is important to keep the traction suture until the first anastomotic knots are placed as pouches contract easily. Using this technique, an anastomosis is possible in most cases in two stages, although sometimes a third one or more is needed. Our analysis of 29 video recordings (4 cases were operated elsewhere) showed the median gap length of 7 vertebral bodies (min. 4, max. 8) for which the final oesophageal anastomosis was possible. If the surgical treatment is started within first days after birth, it is usually not necessary to create a gastrostomy. Our last series of 9 cases (Type A – 4 cases, Type B- 5 cases) was done without any gastrostomy, with median 2 stages (max.4), median 5 days between first and last stage (min 1, max. 11), no electrosurgery, no suction and no intraoperative irrigation either.

Table 3 describes the outcome of infants with long gap OA. There were two intrathoracic leakages in two infants undergoing multistage lengthening. Both were repaired thoracoscopically and continued until undergoing a successful anastomosis. One infant had a perforation of the upper pouch (after anastomosis) and required an emergency oesophagostomy. The child ultimately retained the native oesophagus using an open Collis-Nissen gastroplasty performed later.

There were two instances where, after mobilization of the lower pouch and successful anastomosis, the stomach slipped up into the chest. One was repaired three months later laparoscopically to take the stomach down. The second still has part of the stomach in the chest, but as it is asymptomatic it is being left alone.

## 2. Discussion

Our results in terms of conversion rate, time of procedure, anastomosis success for all types of oesophageal atresia seems to be somewhat different when compared to other centre's published results. I realise it is difficult to draw the general conclusion based on the experience of one centre. However, some facts are worth noting. Different factors such as birth weight, comorbidities, and haemodynamic status play a pivotal role in decision-making with regards to ideal patient selection for thoracoscopic repairs in many centres [3]. Our centre is unique in that from the beginning we have only used thoracoscopic technique so there has been no patient selection criteria. From this view it can serve as a point of reference on what is possible to achieve with a good number of patients and a kind of centralisation. Our department in Wroclaw is the only centre that drains patients from an area of nearly 4 million population, together with admissions from other regions of Poland. We have around 12–18 primary cases a year and the number is increasing. It seems like it is almost like the same number of cases operated by the thoracoscopic approach each year in the whole of the USA [2].

The real number of OA patients being admitted is actually even higher as we also receive patients after failed primary repairs. Since the first thoracoscopic case was done, Wroclaw has become one of the main referral centres in Poland for OA/TOF patients. Starting this year, we are a member of the European Referral Network for rare diseases (ERNICA).

I always say that a sliding knot is essential for perfect oesophageal anastomosis and is the foundation for successful thoracoscopic OA repair. It allows us to approximate suturing tissues together with precise tension control. It should be constantly emphasized that a surgeon must be familiar with all the technical aspects of a sliding knot before proceeding on with the anastomosis. Endoscopic suturing is time-consuming, so perfection is required to limit the time of the procedure. A lack of experience in making perfect endoscopic knots is a main contraindication to the thoracoscopic approach. If there is a considerable distance and significant tension between pouches, one can place two or more sliding knots and to close them step-by-step bringing the pouches together. Usage of multiple sliding knots, that is technically challenging in a small mediastinal space, allows to overcome the tissue tension at anastomosis by evenly distributing the tension between sutures when gradually tightening.

The length of time for the surgical procedure and general anaesthesia is very important for neonates. This longer time for the thoracoscopic approach is one of the main weaknesses quoted in the literature. Our data, however, point to something different that with experience the time is significantly shorter even when compared to an open approach. The first procedure done in our Department took 245 minutes, now it is around one hour (Fig. 2).

The morbidity of thoracotomy is well known and may result in scoliosis and shoulder girdle weakness later in the life. One of the main cited advantages of thoracoscopic approach is avoiding negative consequences of thoracotomy and is confirmed by our data.

Despite the high rate of survival many studies have documented significant overall morbidity related not only to associated malformation but mainly to the surgical technique and operative complications like leakage, stenosis, partial loss of oesophageal stumps

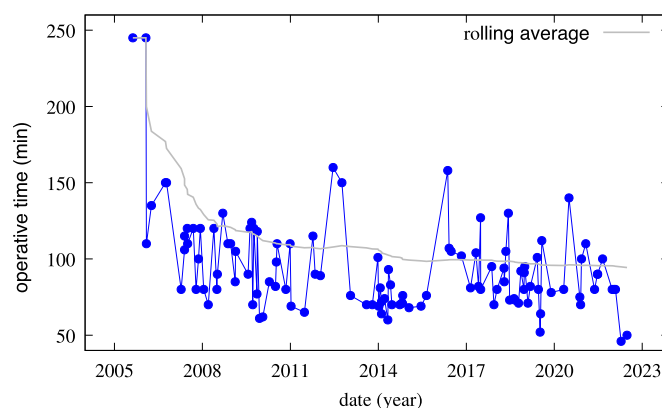


Fig. 2. Operative time for OA with distal TOF - rolling average.

leading to many reoperations and oesophageal replacement even for type C OA. In the last survey of 3290 cases of type C in USA 1017 (31,1%) required gastrostomy placement that is usually done because of swallowing problems or postoperative complications [4]. In my opinion, our better results may be attributed to the meticulous technique of dissection without burning or coagulation. It requires further study to be confirmed.

LGOA represent <10% of all OA cases and requires special attention and highly sophisticated treatment. Most surgeons will see <1 LGOA case every 10 years, hence even the most senior surgeons may be very inexperienced with the challenges in their management [5]. LGOA is always a challenge for a surgeon, and it is hardly ever possible to make primary oesophageal anastomosis. There is no optimal method of surgical management [6]. It seems obvious that they should be treated in tertiary centres specialized in oesophageal surgery, however, that is not the case in many countries and mostly patients are referred only after failed attempts [7]. There were 127 LGOA patients (defined as not possible for a primary anastomosis of the proximal and distal pouches of the oesophagus) identified in the UK between 2015 and 2020 which means about 1.5 cases per year per centre [8]. From this group only 22 cases had different oesophageal lengthening techniques deployed of whom 16 were anastomosed and 13 survived with native oesophagus. It is especially noticeable and strikingly different that in our experience 23 of 27 (85,9%) consecutive LGOA patients (defined as type A and B) were managed by thoracoscopic approach using internal traction and had their own functional oesophagus preserved.

All the data presented here coming from Wroclaw Centre strongly support my suggestion contained in the title of this lecture that the thoracoscopic technique could be a real game changer. As the thoracoscopic technique is demanding and an undoubtedly advanced procedure to change the game requires considerable experience that comes only from the high number of operated cases. Thus, the question of centralisation for special rare congenital malformations comes back to mind. The benefits of care centralisation seem to be obvious, however we refrain from the decision to do it. As paediatric surgeons we are still proud to be “the Kings and Queens or rare diseases” [9]. If we look at two ends of the scale of presented results, it may suggest that mostly patients are treated as an object not as a subject to support the surgeon's ego. A few years ago, I asked one of UK's paediatric surgeons why only a few of OA/TOF patients are operated by thoracoscopic approach. He answered that the paediatric surgery training program includes the open procedure, so he must teach how to do it. Is it possible to offer adult patients open cholecystectomy because we must teach the resident how to do it? In contrast to adult patients, the newborn is unable to express his

or her will. “With no language but a cry, children are looking for better surgical treatment” [10].

The technique is one amongst the many others means which taken together may really help to change the game and the results. The outcome will be a happy life for a baby born with oesophageal atresia. To quote Steven Rothenberg “we have one shot to help such a patient” (personal communication). If we fail at the first attempt Pandora’s box would be open. Is it rational to operate on only 2 or 3 cases a year in a single centre or is it the time for centralisation and close co-operation, as has been done with biliary atresia treatment in the UK [11]?

Lastly, I would like to express my special gratitude to BAPS President Mr Munther Haddad for being my friend, guide, and advocate in the international paediatric surgeon’s world for many years.

## References

- [1] Lobe TE, Rothenberg S, Waldschmidt J, et al. Thoracoscopic repair of esophageal atresia in an infant: a surgical first. *Pediatr Endosc Innov Tech* 1999;3:141–8.
- [2] Etchill EW, Giuliano KA, Boss EF, et al. Association of operative approach with outcomes in neonates with esophageal atresia and tracheoesophageal fistula. *J Pediatr Surg* 2021;56:2172–9.
- [3] Iacona RV, Saxena AK. Thoracoscopic repair of esophageal atresia with distal tracheoesophageal fistula (Type C): systematic Review. *Surg Laparosc Endosc Percutan Tech* 2020;30:388–93.
- [4] Keefe G, Culbreath K, Edwards EM, et al. Current outcomes of infants with esophageal atresia and tracheoesophageal fistula: a multicenter analysis. *J Pediatr Surg* 2022;57:970–4.
- [5] Van der Zee DC, Bagolan P, Faure C, et al. Position paper of INoEA working group on long gap esophageal atresia: for better care. *Front Pediatr* 2017;5:1–3.
- [6] Baird R, et al. Management of long gap esophageal atresia: a systematic review and evidence-based guidelines from the APSA outcomes and evidence based practice committee. *J Pediatr Surg* 2019;54:675–87.
- [7] Svetanoff WJ, Zendejas B, Hernandez K, et al. Contemporary outcomes of the Foker process and evolution of treatment algorithms for long gap esophageal atresia. *J Pediatr Surg* 2021;56:2180–91.
- [8] Brennan K, Cullis P, Yardley I. Oesophageal lengthening by traction in oesophageal atresia: the UK experience. *J Pediatr Surg* 2022;57:187–91.
- [9] Wijnen M, Hulscher J. Centralization of pediatric surgical care in the Netherlands: lessons learned. *J Pediatr Surg* 2022;57:178–81.
- [10] From „The Surgeon and the Child” by Willis Potts, 1959 cited by John H.T.Waldhausen - American pediatric surgical association presidential address 2021 a surgeon’s purpose. *J Pediatr Surg* 2022;57:2–8.
- [11] Davenport M, De Ville de Goyet J, Stringer MD, et al. Seamless management of biliary atresia in England and Wales (1999–2002). *Lancet* 2004;363(9418):1354–7.